

Small aperture intraocular lenses: The new kids on the block



Sathish Srinivasan, FRCSEd, FRCOphth, FACS
Ayr, Scotland, UK

“We keep moving forward, opening new doors, and doing new things, because we’re curious and curiosity keeps leading us down new paths.”

—Walt Disney

Presbyopia is primarily an inevitable, age-related condition causing irreversible loss of the accommodative amplitude of the eye. Despite its ubiquity, the exact mechanism behind presbyopia remains unclear. Worldwide in 2005 over 1.04 billion people were estimated to suffer from presbyopia; the worldwide prevalence is expected to rise to 1.37 billion by the year 2020.¹ Presbyopia affects the quality of life. McDonnell et al.² showed that presbyopia was associated with substantial negative effects on health-related quality of life in a population study based in the United States. The surgical treatment of presbyopia continues to be the holy grail for the ophthalmic surgeon. Currently, the surgical strategies could be broadly classified as techniques that work on the corneal plane and techniques that work on the lenticular plane. Laser refractive corneal surgery has been and continues to be the main tool for correcting presbyopia in the corneal plane with techniques such as monovision and presbylasik.³ Corneal inlays add another dimension to the treatment option at this plane.⁴ However, lenticular techniques seem to be the more popular option for correcting presbyopia, particularly in older patients.

The optics and design of the presbyopia-correcting intraocular lens (IOL) have tremendously advanced in the last few years. The first U.S. Food and Drug Administration-approved multifocal refractive IOL was the Array (Abbott Medical Optics, Inc.), which was approved in 1997. Since then we have seen the introduction of diffractive multifocal, segmental bifocal, trifocal, quadrifocal, and extended depth of focus (DOF) IOLs, and the relaunched light-adjustable IOL.

It has long been recognized that DOF of the eye increases as the pupil diameter decreases, a concept widely adopted in photography (Figure 1). This concept in principle might be helpful in presbyopic patients, providing them adequate vision over a greater range of distances for day-to-day visual tasks. In fact, one simple way of achieving a small pupil is to use a topical miotic agent in combination with other drugs.⁵ Benozzi et al.⁶ reported good distance and near vision at 1 year in young presbyopic patients with their topical cocktail of 1% pilocarpine and 0.1% diclofenac sodium.

Renna et al.⁵ in their series of 14 emmetropic presbyopic patients reported a 2 to 3 line improvement in near vision from baseline in each eye and binocularly. They used a proprietary topical combination of pilocarpine 0.247%, phenylephrine 0.78%, polyethyleneglycol 0.09%, nepafenac 0.023%, pheniramine 0.034%, and naphazoline 0.003%.⁶ Although this idea is intriguing, we need large prospective randomized studies with long follow-up data to assess the long-term efficacy and safety of these pharmacological treatments.

Recently, two IOLs incorporating the small aperture technology have been introduced to the market. The first is the IC-8 small-aperture IOL (Acufocus, Inc.). This is a single piece, aspheric, hydrophobic IOL with an optic size of 6 mm and an overall diameter of 13 mm designed to be implanted within the capsular bag (Figure 2). The optic has a 360-degree square edge and provides a negative spherical aberration of 0.27 μm . Embedded centrally within the optic is a “mask” that has an overall diameter of 3.2 mm with a central aperture of 1.36 mm. This IOL was granted the Conformité Européenne (CE) mark in 2015 and is currently commercially available in Europe, Australia, and New Zealand. When implanted unilaterally in the nondominant eye, with the dominant eye corrected for emmetropia with a monofocal IOL, the small-aperture IOL has been shown to provide excellent range of vision with good safety and patient satisfaction outcomes following cataract surgery.⁷ There is also evidence to show that the IC-8 IOL can improve vision both quantitatively and qualitatively in patients with irregular corneas.⁸

The second type of small-aperture implant is the pinhole device (Xtrafocus Pinhole Implant, Morcher, GmbH). Designed to be implanted as a piggyback lens in the ciliary sulcus this device is made of a black hydrophobic acrylic material. It has an overall diameter of 14 mm and 6 mm occlusive portion with a central aperture of 1.3 mm. It has an optic-haptic angulation of 14 degrees to prevent iris chafing (Figure 3). The 6.0 mm occlusive part of the device has a concave-convex design to prevent contact with the primary IOL located in the capsular bag. Unlike the IC-8 IOL, this device does not have an IOL optic power and purely serves as diaphragm-pinhole. When placed in the ciliary sulcus the pinhole device has been shown to enhance functional vision in previously pseudophakic patients with irregular corneal astigmatism, including keratoconus, post-radial keratotomies (RK), post-penetrating keratoplasty,

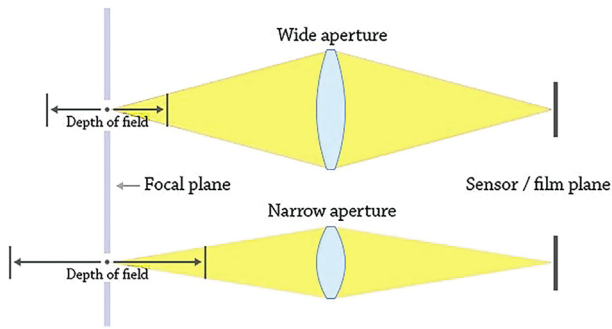


Figure 1. Schematic picture illustrating the depth of focus with different apertures. These aperture sizes can be extrapolated to pupil sizes and the sensor/film plane corresponds to the retinal plane.

and corneal trauma.⁹ In this issue Barnett et al. (page 1042) present a case of combined use of a small aperture IC-8 IOL and secondary piggyback IOL during cataract surgery in a patient with post-RK. In this case the patient's dominant eye was corrected for emmetropia with a monofocal IOL. For the non-dominant eye the highest available power of the IC-8 IOL was placed in the capsular bag. The expected residual refractive error was corrected subsequently with a second surgical procedure during which an aspheric monofocal IOL was placed in the ciliary sulcus leading to excellent refractive outcome in this challenging post-RK eye.

Although we don't have any long-term follow-up data, these novel small aperture IOLs provide additional tools to our surgical armamentarium that one can call upon




Figure 3. Pinhole implant made of black hydrophobic acrylic material with a central aperture of 1.3 mm.



Figure 2. IC-8 single-piece hydrophobic intraocular lens with an embedded diaphragm of 3.2 mm and central aperture of 1.36 mm.

when trying to visually rehabilitate our patients with aberrated corneas and complex anterior segment problems.

REFERENCES

1. Holden BA, Fricke TR, Ho SM, Wong R, Schlenther G, Cronjé S, Burnett A, Papas E, Naidoo KS, Frick KD. Global vision impairment due to uncorrected presbyopia. *Arch Ophthalmol* 2008; 126:1731–17399
2. McDonnell PJ, Lee P, Spritzer K, Lindblad AS, Hays RD. Associations of presbyopia with vision-targeted health-related quality of life. *Arch Ophthalmol* 2003; 121:1577–1581
3. Arba Mosquera S, Alió JL. Presbyopic correction on the cornea. *Eye Vis (Lond)* 2014; 1:5
4. Binder PS. Intracorneal inlays for the correction of presbyopia. *Eye Contact Lens* 2017; 43:267–275
5. Renna A, Vejarano LF, De la Cruz E, Alió JL. Pharmacological treatment of presbyopia by novel binocularly instilled eye drops: A pilot study. *Ophthalmol Ther* 2016; 5:63–73
6. Benozzi J, Benozzi G, Orman B. Presbyopia: A new potential pharmacological treatment. *Med Hypothesis Discov Innov Ophthalmol* 2012; 1:3–5; <https://www.ncbi.nlm.nih.gov/pmc/articles/PMC3939740/>
7. Dick HB, Piovella M, Vukich J, Vilupuru S, Lin L, Clinical Investigators. Prospective multicenter trial of a small-aperture intraocular lens in cataract surgery. *J Cataract Refract Surg* 2017; 43:956–968
8. Schultz T, Dick HB. Small-aperture intraocular lens implantation in a patient with an irregular cornea. *J Refract Surg* 2016; 32:706–708
9. Trindade CC, Trindade BC, Trindade FC, Werner L, Osher R, Santhiago MR. New pinhole sulcus implant for the correction of irregular corneal astigmatism. *J Cataract Refract Surg* 2017; 43:1297–1306



Sathish Srinivasan, FRCSEd, FRCOphth, FACS

University Hospital Ayr, Ayr, Scotland, UK